

Balint's syndrome in a 10-year-old male

Jennifer A Gillen* MRCP FRCOphth, Specialist Registrar in Ophthalmology, Aberdeen Royal Infirmary, Aberdeen;
Gordon N Dutton MD FRCOphth, Consultant Ophthalmologist, Royal Hospital for Sick Children, Glasgow Scotland.

* *Correspondence to first author at Aberdeen Royal Infirmary, Foresterhill, Aberdeen AB25 2ZD, Scotland.*

A 10-year-old male was referred with difficulties at school. He had particular difficulty with reading long words, following the sequence of text down a page, writing words in the correct order, writing words in line, and copying from the blackboard. He had a history of infective endocarditis complicated by intracerebral haemorrhage at the age of three years. Detailed history taking revealed symptoms typical of 'dorsal stream' pathology, namely a deficit of 'vision for action'. This included a spatial disorder of attention (simultanagnosia), defective hand and foot movements under visual control (optic ataxia), and acquired oculomotor apraxia which are consistent with Balint's syndrome. Strategies were suggested for coping with the symptoms and one year later a distinct improvement in adapting to the disability was found.

Balint's syndrome is a triad of visual perceptual difficulty including simultanagnosia, optic ataxia, and psychic paralysis of gaze. Simultanagnosia is an inability to recognize more than one object at a time. Optic ataxia is defective visually guided reaching. Psychic paralysis of gaze is acquired oculomotor apraxia where there is difficulty in directing saccades to an object of interest as well as difficulty in breaking fixation from that object (Hecaen and de Ajuriaguerra 1954, Rizzo 1993, Stasheff and Barton 2001). The syndrome has been reported in adults with a variety of pathologies. The consistent finding supported by clinical examination (Holmes 1918a), post-mortem studies (Balint 1909, Holmes 1918), and neuroimaging (Perenin and Vighetto 1988) is damage localized to the inferior posterior parietal lobes of both hemispheres. This suggests that this area of the brain participates in 'vision for action' (Milner and Goodale 1995, Humphreys et al. 1999). This report describes Balint's syndrome in a 10-year-old male. Written parental consent was obtained.

Case report

A 3-year-old male developed an acute and severe febrile illness with a haemorrhagic skin rash. Initial treatment for presumed meningococcal meningitis failed to improve his condition. A diagnosis of infective endocarditis was made when echocardiography showed vegetations on the mitral valve and staphylococcus aureus grew from blood cultures. Multiple septic emboli were detected throughout the body. Intracerebral haemorrhage from mycotic aneurysms in the right and left parietal lobes required craniotomies to evacuate the haematomata.

The child recovered well and did not require any regular medication. Assessment of visual function was requested when he was ten years old because of difficulty with his education. He had particular difficulty with reading long words, following the sequence of text down a page, writing words in the correct order, writing words in line, and copying from the blackboard.

Detailed history taking revealed that he had symptoms of impaired vision for action. He showed simultanagnosia which manifested as difficulty in negotiating a busy environment like the local shopping centre: he often walked into people as if they were not there. There was faulty visual scanning which manifested as difficulty following moving objects (e.g. a car or an aeroplane) and difficulty reading text. Optic ataxia caused

difficulty climbing down stairs and stepping off kerbs as well as an inability to step onto an escalator moving downwards. He was not learning to read well at school and had started to develop problems with his self-esteem and confidence.

Ophthalmology assessment was surprisingly normal: visual acuity was 6/4 N5 unaided in both eyes. There was no significant refractive error. Stereoacuity was normal at 50 seconds of arc; colour vision was normal. Visual fields were full, using confrontation methods with large moving peripheral targets, but were difficult to plot formally because he could not fix steadily and simultaneously perceive the peripheral target. Ocular motility was abnormal. Although there was no strabismus, there was jerky smooth pursuit. It was very difficult to elicit voluntary saccades from the patient. However, he had no difficulty whatsoever in initiating saccades to an unexpected sound, such as people walking down the corridor outside. Examination of the retina showed multiple tiny areas of chorioretinal scarring consistent with septic emboli in the past. He described shapes, e.g. a triangle, with ease, but had difficulty drawing one. He was hesitant at indicating the centre of a straight line. He could identify events in the 'Cookie Theft' picture from the Boston Diagnostic Aphasia Examination (used to assess simultanagnosia; Goodglass and Kaplan 1972) but took a long time to find a pencil lying on the cluttered desk.

MRI of the brain showed infarction of the right and left posterior parietal lobes (Fig. 1).

During a structured consultation, the child's visual problems were explained to the family in language that they could understand. Strategies for coping with the features of Balint's

syndrome were suggested. An adaptive approach was recommended so that the patient could use his strengths and abilities to compensate for his problems. For example, to compensate for simultanagnosia and problems walking over irregular surfaces when outside, the patient was encouraged to carefully scan the ground ahead in order to plan forward movement. He was encouraged to keep his environment uncluttered, for example, to keep out one pair of shoes for wearing and tidy the rest away, or to keep all toys in a box and play with them one at a time. For efficient reading, phonetic spelling rather than spelling individual letters was found to be helpful, and single-word or well-spaced text was much easier to follow. A brightly coloured card placed under or over each line of text also helped. The patient learned more quickly when listening to the teacher than trying to read from the blackboard. His output increased when dictating his schoolwork to a scribe, rather than attempting to write at speed himself. He was encouraged to use his senses of hearing, touch, and proprioception to locate objects and reach for them instead of relying primarily on vision. Psychic paralysis of gaze (acquired oculomotor apraxia) was overcome by verbal cues and by deliberately scanning the environment in a systematic way.

One year on, objective testing in the clinic showed very similar clinical signs, with excellent visual acuity, normal stereopsis, and normal visual fields to confrontation. However, there was still a degree of optic ataxia, and difficulty with initiating saccades and changing fixation was still present. The child and his family reported that simply having the deficits recognized had been beneficial. The common sense strategies suggested

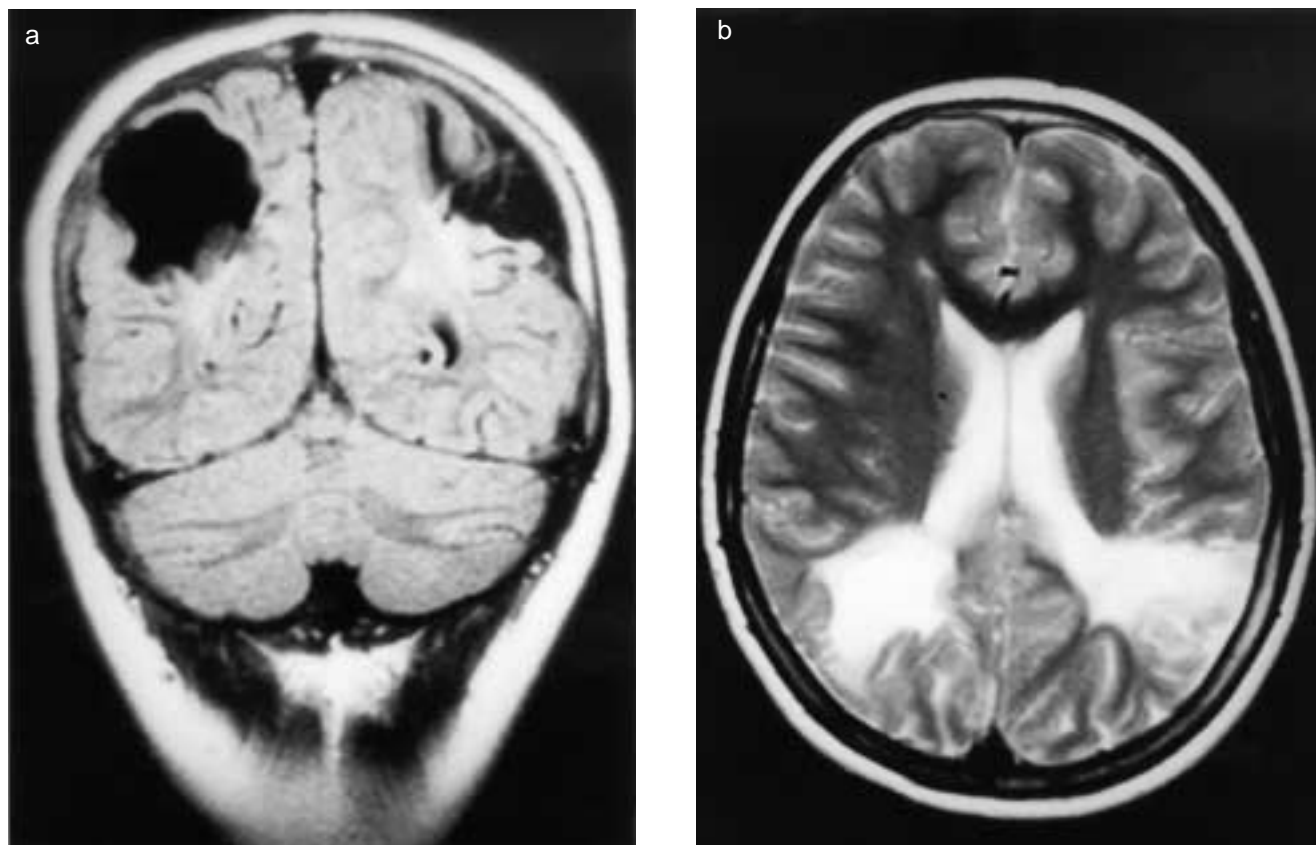


Figure 1: MRI of (a) coronal section and (b) transverse view of patient's brain showing infarcts of both parietal lobes.

were incorporated easily into everyday life and school. He is able to attend mainstream school with the help of a support teacher for less than two hours a week. He has achieved greater independence and his self-esteem has improved. Behavioural problems arising from frustration are less frequent. The patient is able to ride his bicycle safely near his rural home. He appeared, therefore, to have the same condition but had adapted to it much more effectively.

Discussion

Balint's syndrome has three main components: simultanagnosia, optic ataxia, and acquired oculomotor apraxia (psychic paralysis of gaze; Hecaen and deAjuriaguerra 1954). Simultanagnosia is the inability to recognize more than one object at a time and is the spatial disorder of attention described by Balint (1909; Holmes 1918a, Luria 1959, Luria et al. 1962, Rizzo and Robin 1990). More recently it has been recognized that simultanagnosia can vary in degree and may occur in isolation without the other features (Rizzo 1993). Patients with simultanagnosia have difficulty with visual searching and cannot scan large areas of space consistently. Optic ataxia is faulty visually guided reaching. Patients with optic ataxia have difficulty in judging the relative positions of objects and, therefore, misreach (Balint 1909, Holmes 1918a, Luria et al. 1962, Pierrot-Deseilligny et al. 1986, Milner and Goodale 1995). It seems logical that optic ataxia could also affect lower limb movement so that visually guided stepping is clumsy and this would explain the difficulty our patient experienced with climbing down stairs, stepping off kerbs, and using an escalator. Optic ataxia of the legs would also explain the difficulty experienced by five of Holmes' patients who could not find their way round obstacles (Holmes 1918a). Finally, acquired oculomotor apraxia or psychic paralysis of gaze is a difficulty in initiating saccades and inaccuracy of saccades to a target (Balint 1909, Holmes 1918a, Hecaen and deAjuriaguerra 1954, Luria et al. 1962, Pierrot-Deseilligny 1994). Related to this is spasm of fixation where there is difficulty initiating saccades away from a visible point of fixation. Balint's syndrome has been described in adults, and the consistent finding is damage to both parietal lobes (Balint 1909, Holmes 1918, Hecaen and deAjuriaguerra 1954, Luria 1959, Pierrot-Deseilligny et al. 1986, Perenin and Vighetto 1988, Perez et al. 1996). The triad was first reported by Balint in a patient with hypertension who developed profoundly disabling psychic paralysis of gaze, optic ataxia, and spatial disorder of attention (Balint 1909, Harvey and Milner 1995, Husain and Stein 1988). The patient had normal power in his upper limbs, but was unable to perform tasks that required the coordination of vision and movement. His visual fields were full, but he behaved as if he had a left hemianopia. He was found at post-mortem to have 'softenings' in the cortex and underlying white matter of both posterior parietal lobes. Only the dorsal sagittally running fibres were damaged and the ventral layers remained completely intact (Balint 1909). In 1918, Holmes (1918b) reported six patients with very similar features, caused by gunshot wounds involving the posterior parietal lobes. Five of Holmes' patients displayed optic ataxia of the feet, and walked into objects placed ahead, even if the object was pointed out before walking.

Balint's syndrome can be caused by a variety of diseases including ischaemia (multiple strokes; Pierrot-Deseilligny et al. 1986), Alzheimer's disease and cortical atrophy (Perez et

al. 1996), intracranial tumours, brain injury (Holmes 1918a, Luria 1959), infection (Hecaen and deAjuriaguerra 1954), HIV encephalopathy, and progressive multifocal leukoencephalopathy (Rizzo 1993). If the symptoms are not sought, then the syndrome can easily be overlooked, and the disability is, therefore, not managed appropriately. To our knowledge, Balint's syndrome has not been described in children until now.

Interestingly, the pathology of Balint's syndrome corresponds well with our understanding of the visual system of mammals, which has two broad purposes. Firstly, there is 'vision for action' involving processing of information about size, shape, orientation motion, and location of objects. This may be mapped to a 'dorsal stream' arising from the primary visual cortex and terminating in the posterior parietal cortex (the area damaged in cases with Balint's syndrome). Secondly, there is 'visual memory' which involves storing and retrieving images, faces, routes etc. This pathway can be mapped to the 'ventral stream' arising from the primary visual cortex and terminating in the inferior temporal lobes (the area damaged in cases with prosopagnosia, i.e. difficulty recognizing familiar faces or objects; Milner and Goodale 1995, Milner 1997).

The child described above certainly had severe visual perceptual difficulty when he first presented to our clinic. His history revealed problems with simultanagnosia, visual scanning, and processing complex visual information such as schoolwork. Clinical examination confirmed normal visual acuity, stereopsis, and no strabismus. Eye movements were nonetheless abnormal with absent voluntary saccades, despite preserved saccades to unexpected auditory stimuli or tactile stimuli.

Rehabilitation of patients with Balint's syndrome can employ various strategies (Perez et al. 1996, Al-Khawaja and Haboubi 2001). An adaptive or functional approach can use the strengths and abilities of the patient to compensate for the problem. Intensive verbal cues can allow the patient to apply learned behaviour to new tasks. Organization can improve reaching for objects and scanning of surroundings. Finally, a multicontext approach where a targeted strategy is practised in different environments may help (Al-Khawaja and Haboubi 2001). If this does not work, cognitive remediation can help (Perez et al. 1996). A remedial approach using table-top activities or sensorimotor exercises can train specific perceptual skills and then generalize these to all activities of daily living.

The first step for this patient was to acknowledge his problem and for the characteristics of the disorder to be explained to him and to his parents. He was encouraged to use his strengths and abilities to compensate for his visual perceptual difficulties. It was emphasised that he should be given information in a form that was easy for him to assimilate so that he could make progress with his education.

One year later objective assessment of his clinical signs showed little change suggesting that he had learned to cope with his stable disability much better. There was a subjective improvement in his symptoms and his performance at school had improved. His self-esteem and confidence had improved, and behavioural problems related to frustration and despair were improving.

Conclusion

Clearly, it is especially important to look for cognitive disorders

of visual function in children as they can be a source of profound visual disability, even if eye examination is remarkably normal (Good et al. 1994). Simple, common sense strategies for rehabilitation can be effective.

DOI: 10.1017/S001212203000641

Accepted for publication 4th December 2002.

References

- Al-Khawaja I, Haboubi NHJ. (2001) Neurovisual rehabilitation in Balint's syndrome. *J Neurol, Neurosurg Psychiatry* 70: 416. (Letter.)
- Balint R. (1909) Seelenlahmung des 'Schauens', optische Ataxie, raumliche Störung der Aufmerksamkeit. *Monatsschrift für Psychiatrie und Neurologie* 25: 51–81.
- Good WV, Jan JE, DeSa L, Bearkovich AJ. (1994) Cortical visual impairment in children. *Surv Ophthalmol* 38: 351–364.
- Goodglass H, Kaplan E. (1972) *The Boston Diagnostic Aphasia Examination*. Philadelphia: Lea and Febiger.
- Harvey, M, Milner AD. (1995) Balint's patient and psychic paralysis of gaze, optic ataxia, and spatial disorder of attention. *Cognit Neuropsychol* 12: 261–81.
- Hecaen H, deAjuriaguerra J. (1954) Balint's syndrome (psychic paralysis of visual fixation) and its minor forms. *Brain* 77: 373.
- Holmes G. (1918a) Disturbances of visual orientation. *Br J Ophthalmol* 2: 449–468.
- Holmes G. (1918b) Disturbances of visual orientation (concluded). *Br J Ophthalmol* 2: 506–516.
- Husain M, Stein J. (1988) Rezso Balint and his most celebrated case. *Arch Neurol* 45: 89.
- Luria AR. (1959) Disorders of simultaneous perception in a case of bilateral occipitoparietal brain injury. *Brain* 82: 437.
- Luria AR, Pravdina-Vinarskya EN, Yarbus AL. (1962) Disturbances of ocular movement in a case of simultanagnosia. *Brain* 86: 219.
- Milner AD, Goodale MA. (1995) Chapter 4 Disorders of spatial perception and the visual control of action. In: *The Visual Brain in Action*. Oxford, UK: Oxford University Press.
- Milner AD (1997) Vision without Knowledge. *Phil Trans R Soc London* 352: 1249–1256.
- Perenin MT, Vighetto A. (1988) CT reconstructions of lesions responsible for optic ataxia and visual neglect. *Brain* 111: 643–74.
- Perez FM, Tunkel RS, Lachmann EA, Nagler W. (1996) Balint's syndrome arising from bilateral posterior parietal cortical atrophy or infarction: rehabilitation strategies and their limitation. *Disabil Rehab* 18: 300–4.
- Pierrot-Deseilligny C, Gray F, Brunet P. (1986) Infarcts of both inferior parietal lobes with impairment of visually guided eye movements, peripheral visual inattention and optic ataxia. *Brain* 109: 81. (Case Report).
- Pierrot-Deseilligny C. (1994) Saccade and smooth pursuit impairment after cerebral hemispheric lesions. *Eur Neurol* 34: 121–34.
- Rizzo M, Robin DA. (1990) Simultanagnosia: a defect of sustained attention yields insight on visual information processing. *Neurology* 40: 447–455.
- Rizzo M. (1993) Balint's Syndrome and associated visuospatial disorders. *Balliere's Clin Neurol* 2: 415–37.
- Stasheff SF, Barton JJ. (2001) Deficits in cortical visual function. *Ophthalmology Clinics of North America* 14: 217–42.

FOLIC ACID & THE PREVENTION OF NEURAL TUBE DISORDERS: ARE WE GETTING THE MESSAGE ACROSS TO THOSE WHO NEED IT?

ROYAL SOCIETY OF MEDICINE, WIMPOLE STREET, LONDON, UK.
WEDNESDAY 7TH MAY 2003: 9.00–18.00

**SPONSORED BY THE LITTLE FOUNDATION & MAC KEITH MEETINGS
SUPPORTED BY THE SOCIETY FOR SPINA BIFIDA & HYDROCEPHALUS: ASBAH**

ORGANISER:

Jean-Pierre Lin, London, UK

SPEAKERS INCLUDE:

Mary Seller, London, UK; Waney Squier, Oxford, UK; Kate Langford, London, UK; Claire Rozette, London, UK; Joan Noble, London, UK; Nick Wald, London, UK; John Scott, Dublin, Eire; David Wald, Southampton, UK; Lenore Abramsky, London, UK; Colin Michie, London, UK; Godfrey Oakley, USA; Claire Rayner, London, UK

FOR FURTHER INFORMATION CONTACT:

Rachel Beresford-Peirce on 0207 290 3934 or email: MacKeith@rsm.ac.uk
Royal Society of Medicine, 1 Wimpole St, London W1G OAE

